



THE CAVUS FOOT: Biomechanical and Postural Considerations/ Orthotic Treatment

BY **JOE COLETTA, PTA, C.PED.**

Read This Article, Take Survey to Earn Continuing Education Points

Pedorthic Footcare Association (PFA) now offers Continuing Education Points (CEPs), approved by the American Board for Certification in Orthotics, Prosthetics & Pedorthics (ABC) and the Board of Certification/Accreditation International (BOC), via specially designated articles within *Current Pedorthics* magazine.

To take advantage of the program, thoroughly read the adjacent article, “The Cavus Foot: Biomechanical and Postural Considerations/Orthotic Treatment,” and then visit www.pedorthics.org and click on the Continuing Education Opportunities tab to purchase the 10-question quiz associated with this article. CEP quizzes cost \$15 for members and \$25 for non-members. The quizzes are worth 1.0 Scientific or Business CEP, depending on the content. Successful completion of the quiz will result in 1.0 CEP reported directly to ABC and BOC at the end of each quarter.

This article is the fifth CEP-eligible article in *Current Pedorthics*. Look for additional CEP-eligible articles in future issues of the magazine.

If you have any questions, contact Lauren Kemp, PFA education coordinator, at (800) 673-8447 or e-mail info@pedorthics.org.

CAVUS FOOT DEFORMITIES ARE COMMONLY ASSOCIATED WITH NEUROLOGICAL DISORDERS SUCH AS CHARCOT-MARIE-TOOTH DISEASE, LEG LENGTH DISCREPANCY AND BIRTH DEFECTS SUCH AS A CLUBFOOT DEFORMITY, ETC. HOWEVER, CAVUS FEET ACTUALLY OCCUR QUITE OFTEN NATURALLY AS A FOOT TYPE, PERHAPS AS A RESULT OF GENETIC TRAITS. WHILE OVERLY PRONATED FOOT TYPES ARE MORE COMMON, THE HIGH ARCHED CAVUS FOOT HAS THE POTENTIAL FOR SIGNIFICANT PATHOLOGICAL FINDINGS AT THE FOOT, LOWER EXTREMITY AND PELVIS. CAVUS FOOT TYPES CAN ALSO BE VERY CHALLENGING FOR THE PRACTITIONER TO TREAT ORTHOTICALLY. THE SCOPE OF THIS ARTICLE WILL REVIEW THE ETIOLOGY OF A CAVUS FOOT TYPE, COMMON SIGNS AND SYMPTOMS, ORTHOTIC TREATMENT AND POSTURAL CONSIDERATIONS.

Components of the Cavus Foot

The cavus foot is a “multiplanar” deformity (see Figure 1) with malalignments occurring in several anatomical planes that includes the rearfoot, forefoot and first ray. This usually includes the following malalignments:

- Uncompensated rearfoot varus;
- Forefoot valgus;
- Rigid plantarflexed first ray; and
- Forefoot equinus.

Common signs and symptoms include lateral ankle instability, peroneal tendonitis, heel pain, sesamoiditis and low back pain, to name a few. Classic callus patterns are the first and fifth metatarsal heads.

THE CAVUS FOOT

Rearfoot Component (Uncompensated Rearfoot Varus)

A totally uncompensated rearfoot varus exists when the subtalar joint (STJ) cannot pronate and therefore lacks calcaneal eversion (frontal plane deformity). As a result, the medial condyle of the calcaneus cannot be lowered to the ground without other adaptations of the foot and lower extremity in order to load the medial column of the foot (see **Figure 1**).

The result of this excessive varus rearfoot alignment is a locked position of the midtarsal joint (MTJ), resulting in a rigid foot type with lack of natural shock attenuation. The uncompensated rearfoot varus alone, if coupled with a neutral forefoot alignment, is often referred to as a subtle cavus foot. These “under-pronators” have a tendency to overload the lateral column of the foot and often acquire an excessive toe-out gait from the hips in order to more easily load the medial column. It is when this uncompensated rearfoot varus is coupled with a malaligned forefoot that we begin to see the true cavus foot with lateral instability.

Forefoot Component (Forefoot Valgus/Plantarflexed First Ray)

A structural forefoot valgus may be caused by excessive derotation of the talar head and neck during early childhood development (frontal plane deformity). This may be mimicked or exacerbated by the presence of a rigid plantarflexed first ray (sagittal plane deformity) (see **Figure 2**). The presence of this forefoot alignment, when coupled with an uncompensated rearfoot varus, will result in a true cavus foot type with the potential for lateral instability of the foot and ankle. If the forefoot valgus/plantarflexed first ray is significant, there will be potential for oversupination, particularly in the propulsive phase of gait.

Forefoot Equinus

This is a sagittal plane deformity, occurring either at the tarsometatarsal joint or Chopart’s joint that results in plantar flexion of the forefoot relative to the rearfoot. This forefoot alignment is often combined with equinus at the ankle as well (see **Figure 3**). In the foot, the forefoot equinus contributes to the excessively high lateral longitudinal arch in the cavus foot, but it also contributes to more proximal postural clinical findings such as ankle equinus, knee hyperextension (recurvatum) and an increased lumbar lordosis.

Knee Recurvatum

Knee recurvatum (hyperextension) is a common clinical finding with oversupinated feet, particularly the cavus foot (see **Figure 3**). External tibial rotation is a component of supination, and excessive tibial external rotation will occur with the oversupinated foot. The knee will be forced into extension as the tibia externally rotates, often to an excessive degree. In addition, with the forefoot and ankle equinus, the body’s center of gravity may be shifted posteriorly to the lateral malleolus as the knees hyperextend.

Lumbar Lordosis

As the knees are forced into hyperextension, the body’s center of gravity is forced posteriorly to the lateral malleolus. As a result, the individual may often perform an anterior pelvic tilt in order to bring the center of gravity back over the ankles. This increases the neutral lumbar lordosis to an excessive lumbar lordosis, which often results in lumbosacral compression and low back pain. A crucial component to the orthotic construction to address this problem is the use of heel lifts to bring the floor up to the heels instead of the heels being forced to the floor due to the equinus.

Gait Analysis

The following is a brief summary of common findings in gait for the cavus foot:

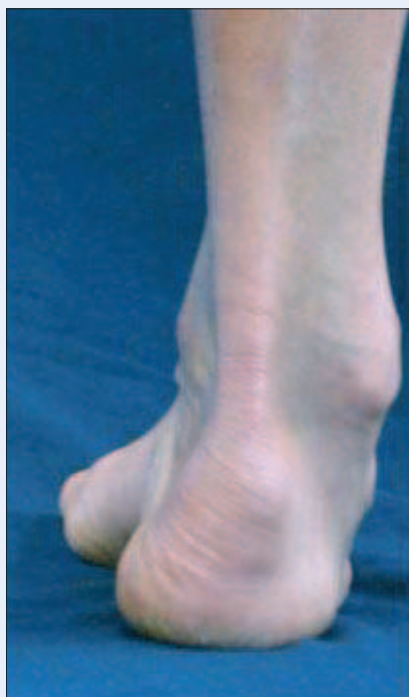

Figure 1

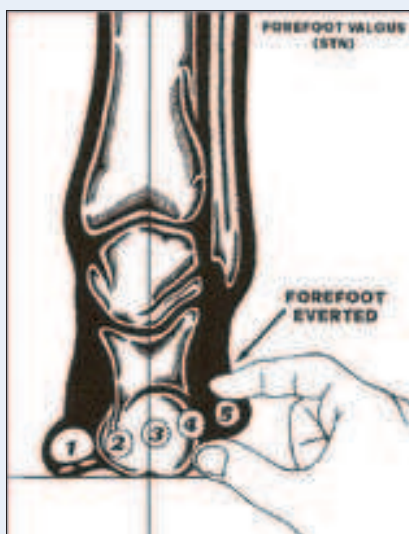


Figure 2

- At contact phase, the rearfoot is in an excessive varus alignment relative to the floor. As the foot loads to foot-flat, there is typically no calcaneal eversion, resulting in a rigid foot with no shock attenuation and the potential for early supination.

In midstance, the MTJ remains locked as the STJ was unable to pronate.

- In propulsion, as the heel leaves the ground, the forefoot valgus/plantarflexed first ray take over, resulting in excessive oversupination with significant potential for lateral instability at the ankle (see Figure 4).

Another test to determine whether to use lateral forefoot posting is the Lateral Block Test (see Figure 5). Have the patient raise his or her heels off the floor to simulate propulsion and to allow the full effect of the FF valgus/plantarflexed first ray. Observe the oversupination of the rearfoot and ankle. Then place a block of approximately one-quarter-inch (a magazine works well) under the lesser metatarsal heads (2-5) and notice the immediate reduction of supination. A reduction in supination with the lateral block is a good indication that lateral forefoot posting with a first ray cutout is indicated in the orthotic design.

Orthotic correction should be primarily based on the biomechanics of the foot type and not just the symptoms.

Weight-bearing Tests

The key to controlling the oversupination will be the use of lateral forefoot posting with a first ray channel and cutout. To determine the level of lateral instability, there are two clinical tests that can be performed. The first test is something I do with every orthotic evaluation, which is to simply observe the motion at the foot from subtalar neutral (STN) to a relaxed calcaneal stance (RCS). Place the standing patient's feet into STN and watch what movement occurs as he or she moves into RCS. More often than not, the patient will need to supinate his or her feet a certain degree to get to a neutral position in standing, after which the patient will typically pronate into RCS. In a true cavus foot, the patient may actually need to pronate his or her feet in order to get to a standing neutral position.

When asked to relax, supination will be observed as the medial column is overloaded due to the forefoot valgus/plantarflexed first ray and supination is required to sufficiently load the lateral column (see Figure 1).

Orthotic Considerations

When thinking about the specific orthotic corrections (see Figure 6), it is important to consider the primary components of the cavus foot type and the biomechanical implications. Orthotic correction should be primarily based on the biomechanics of the foot type and not just the symptoms.

- The ideal negative impressions are plaster non weight bearing STN slipper casts. This plaster model will give the most accurate portrayal of the FF valgus alignment relative to the heel bisection, and it will also give the most detail to the plantarflexed first ray and forefoot equinus.
- Minimal arch fill. Many practitioners are "gun shy" as to how much to support the arch of the cavus foot. I personally find minimal arch fill is indicated. Cavus feet actually "crave" arch support the most as all of their weight is carried through the forefoot and heel, with minimal to no weight taken through the arch. Gently supporting the arch will not induce

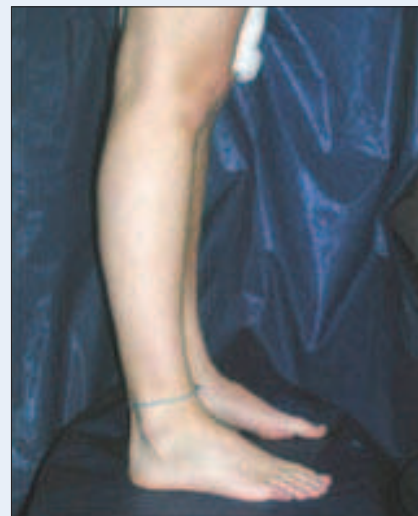

Figure 3

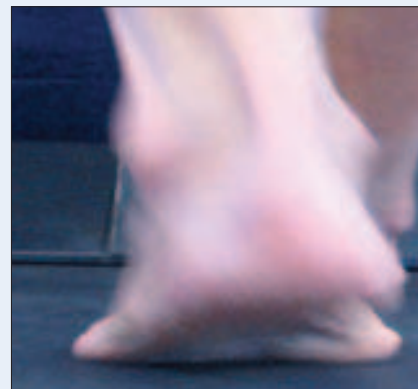


Figure 4

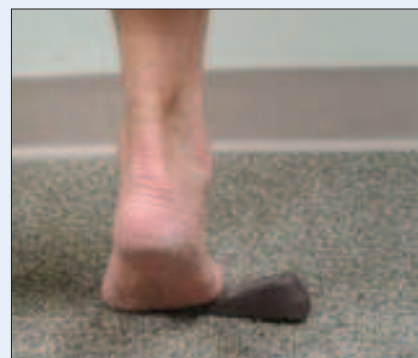

Figure 5



Figure 6

THE CAVUS FOOT

oversupination if the orthotic is posted properly, and it will provide the benefit of unloading the heel and forefoot.

- Extrinsic lateral forefoot posting (lateral block test) will usually be necessary to control oversupination in propulsion.
- First ray channel and cutout to accommodate the rigid plantarflexed first ray, which increased the effectiveness

of the lateral forefoot posting and reduce pressure on the sesamoids.

- Fifth ray channel: I often incorporate a fifth ray channel as well (no cutout for the fifth metatarsal head though) to help reduce pressure on the fifth ray due to the equinus position of the forefoot.
- Lateral Heel Clip: High lateral heel cup to help keep the heel from

sliding laterally off of the orthotic.

This lateral heel clip may also work as a proprioceptive reminder; at contact phase, the heel will feel the lateral flange of the heel cup and will naturally want to center itself toward midline to get away from the lateral heel cup.

- Heel lifts: I typically incorporate one-eighth to one-fourth inch heel lifts, depending on the severity of the forefoot and ankle equinus, to decrease the degree of knee hyperextension and lumbar lordosis.
- Lateral Rearfoot posting? The rearfoot is typically posted at the STJ neutral position. Lateral posting of the rearfoot beyond this neutral position is typically not helpful and may actually cause injury or discomfort. The uncompensated rearfoot varus of this magnitude is often anatomically unable to evert beyond its neutral position. Any attempt to laterally post the STJ from this neutral position will usually not evert the STJ. It will apply a pronatory force to the ankle and may actually gap the medial knee joint, causing medial knee pain and potential for injury.
- Materials: Practitioners have a wide variety of material options at their disposal. Semi-rigid materials should be utilized in order to have effective control of oversupination. Soft orthotics are often prescribed, but given the rigidity of this foot and the inherent lateral instability, soft foam materials will not hold up under the heavy impact of this foot type, and the soft materials will also not provide the stability needed for lateral posting. ■

The Most Versatile Material on the Market!

DS2000 Euro International

endless possibilities

Sheets available in 2 thicknesses:
2.4 mm Rigid
1.4 mm Semi-Rigid

4 Different Sheet Sizes Available:
1.4 mm 4x8": 5-2002-1.4-4x8
2.4 mm 4x8": 5-2002-2.4-4x8
1.4 mm 5x9": 5-2002-1.4-5x9
2.4 mm 5x9": 5-2002-2.4-5x9
1.4 mm 5x12": 5-2002-1.4-5x12
2.4 mm 5x12": 5-2002-2.4-5x12
1.4 mm 20x24": 5-2002-1.4-20x24
2.4 mm 20x24": 5-2002-2.4-20x24



The material properties of the acryl/fiber composite plies make thermoplastic molding as well shape cutting possible. Due to those properties, DS has a wide variety of uses in the O&P Field.

The advantage is the combination of materials. We are working with Knitted Glass Fiber Fabric in combination with Acryl Resin.

This material has very special forming features. Every loop in the knit is tightly organized. That means every loop can be compressed or stretched in a special way. The material can absorb tension and pressure forces where the forming features come from.





5906 Breckenridge Pkwy Ste G
Tampa, FL 33610
800-378-2480 fax: 813-246-5998
www.eurointl.com sales@eurointl.com



Joe Coletta, PTA, C.Ped., has been a Certified Pedorthist since 1993. Coletta is currently director of education and training for QuadraStep Orthotics. He works

closely with manual physical therapists and soft tissue therapists regarding the relationship of foot function to low back/ pelvis function and travels extensively teaching one- and two-day continuing education programs.

ACOR[®]

For EVERY walk of LIFE!

Your source for the highest quality pedorthic/orthotic products at competitive prices.

In stock for immediate shipment.

Call today!

800-237-2267

Download our Catalogs:

www.acor.com

Visit us:

AOPA, booth #824
Las Vegas, NV
Sept 19-22, 2011

PFA, booth #100
Albuquerque, NM
Nov 10-13, 2011

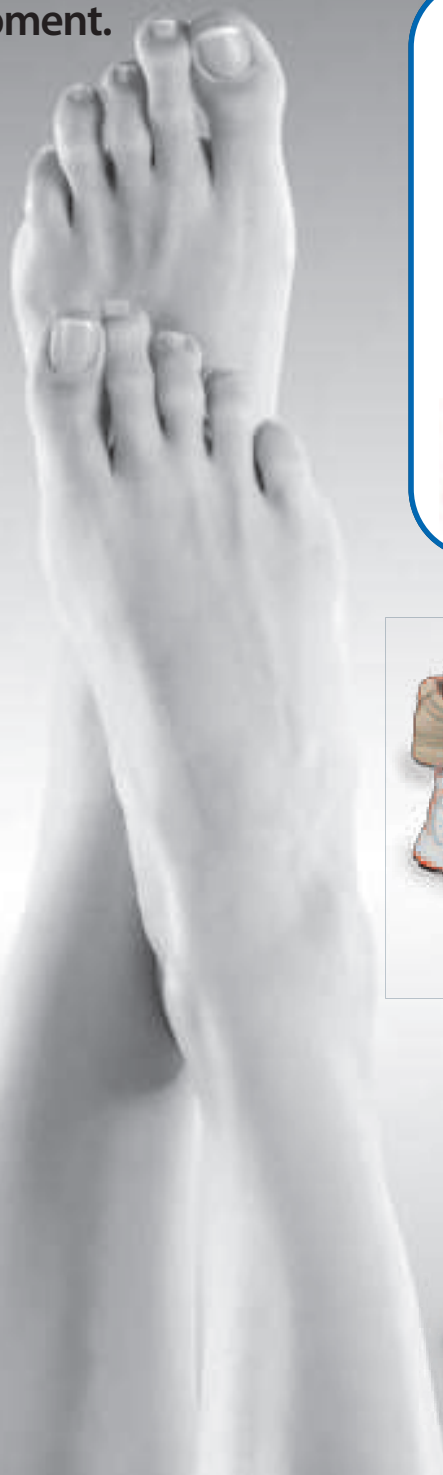

MATERIALS

CUSTOM ORTHOTICS



PRE-FABRICATED ORTHOTICS



STOCK FOOTWEAR
No Return Shipping or Restocking Fees!



CUSTOM FOOTWEAR

www.acor.com

cs@acor.com

Look for us:

